

DETECTION OF *HELICOBACTER* ANTIGEN IN STOOL SAMPLES AND ITS RELATION TO *H. PYLORI* POSITIVE CHOLECYSTITIS IN EGYPTIAN PATIENTS WITH CHRONIC CALCULAR CHOLECYSTITIS

By

EHSAN H. HASSAN¹, SHAWKAT S. GERGES², REHAB AHMED³,
ZEINAB M. MOSTAFA⁴, AZZA HASSAN⁵, HAGER ABD AL-HAMID⁵,
HEBA ABD EL-GALIL⁶ AND SUZAN THABET¹

Department of Pathology¹, Department of Surgery², Department of General Medicine Department of Radiology⁴, and Department of Medical Parasitology & Immunology⁵, National Hepatology and Tropical Medicine, Research Institute^{1,2,3,4,5}, Cairo, and Department of Community⁶, Faculty of Medicine, Al-Azhar University, Cairo, Egypt (*Corresponding author: e-mail:rehabahmed71@yahoo.com)

Abstract

Evidences supporting the association between *H. pylori* infection and chronic cholecystitis could be found by using direct culture or staining of *H. pylori* in gallbladder tissues as well as indirect techniques. Stool antigen test has been widely used due to its non-invasive nature. Various stool antigen tests were developed to detect *H. pylori* using an enzyme immunoassay (EIA) based on monoclonal or polyclonal antibodies

This study evaluated the frequency of *H. pylori* antigen in stool samples of patients with chronic calculous cholecystitis as regard gall bladder histopathological changes. Fifty patients were included presented with symptomatic cholelithiasis recruited from the outpatient clinic of National Hepatology and Tropical Medicine Research Institute during 2014-2015. Full history and clinical examination and abdominal ultrasonography were performed. Stool samples were collected, prepared and examined for detection of *H. pylori* antigen. Cholecystectomy was done for all patients; 45 patients (90%) by laparoscopic Cholecystectomy and 5 patients (10%) by open surgery and removed gallbladders were submitted to pathology department for detection of *H. pylori* in tissue under microscope using Giemsa stain. The results showed that (82%) were females with mean age (42.6±1 years). The mean BMI was (29±7.2) *H. pylori*-specific antigen in stool samples was detected in 40% of patients and 38% were detected in patients; tissue, with significant correlation between *H. pylori*-specific antigen in stool and in tissue. Histopathological pictures infection in tissue were 68.4% mucosal erosions, 63.2% mucosal atrophy, 57.9% mucosal hyperplasia, 26.3% metaplasia, 42.1% muscular hypertrophy, 26.3% fibrosis, but lymphoid aggregates were in 42.1% of cases.

Key words: *Helicobacter pylori*, chronic calculous cholecystitis, ELISA, histopathology.

Introduction

Helicobacter pylori, a gram-negative bacterium found on the luminal surface of the gastric epithelium, was first isolated in 1983 (Warren *et al*, 1983). Infection with *H. pylori* is a cofactor in the development of three important upper gastrointestinal diseases: duodenal or gastric ulcers (El-Omar *et al*, 1995), gastric cancer (Hansen *et al*, 1999), and gastric mucosa-associated lymphoid-tissue (MALT) lymphoma (Parsonnet *et al*, 1994). It was thought that *H. pylori* pathogenic effects were limited to the stomach, however, its existence in extra gastric structures was reported (El-Fakhfakh *et al*, 2014). *Helico-*

bacter pylori and *H. bilis* were detected in the bile and gallbladder in 75 % of patients with gallbladder cancer and more than 50% with chronic cholecystitis (Murphy *et al*, 2014). Evidences supporting association between *H. pylori* and chronic cholecystitis were demonstrated by direct culture or staining of gallbladder tissues and by PCR, ELISA using *H. pylori*-specific genes or antibodies (Lee *et al*, 2010).

Various stool antigen tests were widely used due to their non-invasive nature tests for detection of *H. pylori* as the enzyme immunoassay (EIA) based on monoclonal or polyclonal antibodies (Gisbert *et al*, 2004).

A systematic review of the stool antigen test in untreated patients with *H. pylori* showed overall sensitivity; 91%, specificity; 93%, positive predictive, 92% and negative one; 87% (Gisbert *et al*, 2006). The Warthin stain showed *H. pylori* existence in 13.5% (524) of gall-bladders mucosa in cholecystitis patients (Dong *et al*, 2007). So, it was an important discovery when a few investigators found *H. pylori* in some gallbladders of some patients with chronic cholecystitis that could be a key factor (Kawaguchi *et al*, 1996). The presence of *H. pylori* in the biliary tract was in 50-60 % of patients (Ghzal *et al*, 2001). *H. pylori* in the gastric and duodenal mucosa are much more common. In Egypt and other countries, *H. pylori* were 80% of population (WGO 2011). Chronic cholecystitis was commonly associated with gallstone disease and cholecystitis and gallstones caused epithelial hyperplasia of gallbladder mucosa or cancer (Jafri *et al*, 2010).

This study evaluated the *H. pylori* antigen in stool samples of patients with chronic calcular cholecystitis and its relation to histopathological changes of gall bladder.

Patients, Materials and Methods

This was a descriptive cross sectional study carried on 50 patients; 9 males & 41 females with symptomatic cholelithiasis complain of dyspepsia and/or right upper hypochondrial pain recruited from the National Hepatology and Tropical Medicine Research Institute (NHTMRI) outpatient clinic from June 2014-June 2015. The recruitment and experimental protocol study was approved by NHTMRI Ethical Committee. Patients with acute cholecystitis, tumors and/or previously treated with antibiotics and proton pump inhibitors were excluded

After full history and clinical examination; abdominal ultrasonography was done to confirm calcular cholecystitis performed by expert radiologist. Small piece of stool samples (~5mm in diameter; ~150mg) added and diluted into 1ml of sample treatment solution in a test tube and mixed thoroughly.

H.pylori infection was detected by -specific antigens in stool sample (fecal antigen test) and by ELISA (commercially available).

Purified *H. pylori* antibody was coated on surface of microcells. An aliquot of diluted stool sample was added to wells, and the *H. pylori* antigens, if present, bind to the antibody. Unbound materials were washed. After adding enzyme conjugate, it binds to antibody-antigen complex. Excess enzyme conjugate was washed and TMB Chromogenic substrate was added. The enzyme conjugate catalytic reaction stopped at a specific time, and the color generated intensity was proportional to antigen amount, and read by a micro well reader compared in a parallel manner with calibrator and controls. Interpretation: negative <15ng/ml, positive >20ng/ml, Borderline: 15-20ng/ml

Cholecystectomy was done for all patients, 45 (90%) by laparoscopic cholecystectomy and five (10%) by open surgery. The gallbladders were submitted for histopathological detection of *H. pylori* in tissue samples. Gallbladder tissue samples were fixed in 10% buffered formalin, embedded in paraffin wax 5- μ m thick sections and stained with hematoxylin and eosin, with Giemsa and sealed with DPX mount.

Statistical analysis: Data coding was done manually, and analyzed by SPSS program version 16. Descriptive and analytical analyses were done. Mean standard deviation "SD" that measured central tendency and dispersion of quantitative data and expressed in numbers and percentage. Analytical statistics using test of significance as: a- Unpaired *t*-test: for quantitative data of two independent samples, b-Chi square-test (χ^2) to compare qualitative data, and correlation coefficient was done. The level of significance was taken at $p \leq 0.05$

Results

The range of age was 18-61 (mean age 42.6 \pm 11years), 52% of patients were from urban areas. The mean BMI was (29 \pm 7.2), most of patients were obese (44%), the mean

cholesterol level was 219 ± 145 , and the mean of triglycerides was 121 ± 52 . *H. pylori*-specific antigen in stool samples was detected in 40% of patients while it was detected in tissue in 38% of patients. The most predominant histopathological finding was muscular hypertrophy (22/50) varied from mild (7/50), moderate (10/50) and severe (5/50). Other changes as mucosal atrophy (42%) varied from mild (24%) to moderate (18%) & mucosal erosion (42%) while lymphoid aggregates all through the mucosa (24%), fibrosis of the gallbladder wall (22%), mucosal hyperplasia (36%) varied from mild (26%), moderate (10%), metaplasia (10%) and dysplasia (6%) with mild degree (4%) to moderate (2%).

According to the presence or absence of *H. pylori* antigen in stool, patients were divided in two groups: GI (Ag+ve in stool) 80% females, with a mean age of 44.2 years, of which 65% were from urban areas, in GII (Ag -ve in stool), 83.3 females with a mean age of 41.5 years 53.3% were from rural areas, without significant difference as regard sex, mean age and residence, with BMI higher among GI (31.7Kg/m^2) than GII (27.1Kg/m^2) with significant ($p=0.02$). Cholesterol level was higher in GII (247mg/dl) than GI (177.8mg/dl) & mean triglycerides was higher in GI (127mg/dl) than GII (116 mg/dl), but without significant difference. GI (65%) had mucosal erosions, but GII, (26.7%) had erosions; GI (65%) had mucosal atrophy but GII (30%) had atrophy, and GI (40%) had mucosal hyperplasia but GII (33.3%) had hyperplasia. GI (15%) had metaplasia, but GII (6.7%) had metaplasia, GI (40%) had muscular hypertrophy and (4%) had fibrosis but GII (46.7%) had hypertrophy and (23.3%) had fibrosis; cases with lymphoid infiltration were (35%) in GI and (16.7%) in GII, without significant difference except for mucosal erosion and mucosal atrophy were significance ($p=0.007$ & 0.02 respectively). While according to comparison between patients with *H. pylori* +ve and *H. pylori* -ve in tissue, patients were

divided into two groups: GI (+ve in tissue), 78.9% were females, with a mean age of 46.2 years, 68.4% were from urban areas, in GII (-ve in tissue), 83.9% were females with a mean age of 40.4 years 51.6% were from rural areas, without significant difference as regarded sex, mean age and residence. BMI mean was higher in GI (30.6Kg/m^2) than GII (28Kg/m^2) without significance, mean of cholesterol level was higher in GII (244mg/dl) than GI (179mg/dl) and mean triglycerides was higher in GI (125mg/dl) than GII (118mg/dl) without significant difference between both groups. GI 68.4% had mucosal erosions, in GII, 25.8% had erosions. GI, 63.2% had mucosal atrophy while GII, 32.3% had mucosal atrophy, GI (57.9%) had mucosal hyperplasia while in GII (6%) had hyperplasia, in GI (26.3%) had metaplasia, and none in GII. GI (42.1%) had muscular hypertrophy and (26.3%) had fibrosis, GII (45.2%) had hypertrophy and (19.4%) had fibrosis. GI all with lymphoid infiltration were (42.1%), GII (12.9%) with significant differences regarding mucosal erosions ($p=0.003$), mucosal atrophy ($p=0.03$), mucosal hyperplasia ($p=0.012$), metaplasia ($p=0.003$) & lymphoid infiltration ($p=0.02$). There was significant correlation between *H. pylori*-specific antigen in stool and in tissue.

Discussion

In the present study, fifty patients were included; all presented with symptomatic cholecystolithiasis with mean age was (42.6 ± 11 years) ranged from 18-61 years. The majority of patients (82%) were females. *H. pylori* infection was detected by identifying *H. pylori* -specific antigens in stool samples and detection of *H. pylori* in all gallbladder tissue specimens under microscope using Giemsa stain. *H. pylori* -specific antigen in stool samples was detected in 40% of patients while it was detected in tissue in 38% of patients. This agreed with Cintia *et al.* (2003) who found *Helicobacter* DNA in 42.9% of gallbladder tissue of 46 Brazilian patients with choleli-

thiasis and 18 without cholelithiasis. Apostolov *et al.* (2005) found *Helicobacter* DNA in 16/22 (73%) of gallbladders of Ukrainian patients with cholecystitis by immunohistochemistry. In Egypt Fekry *et al.* (2014) reported that gastroscopy with gastric or duodenal *H. pylori* urease test and in serum were done for 140 patients before operation. After cholecystectomy, gastric rapid urease test was positive in 40.7%. The gallbladder rapid urease test was positive in 25%. In 24 patients both gastric and gallbladder mucosa tested positive for rapid urease test. In 28 patients, the gastric urease test was positive

while the gallbladder mucosa tested negative. In 13 patients, the gallbladder mucosa tested positive while the gastric mucosa was negative. There was a significant correlation between the rapid urease test in the gallbladder and gastric or duodenal mucosa ($P = 0.002$). Modified Geimsa stained specimens revealed that *H. pylori*-like bacteria were detected in 63.6%. There was a significant correlation between gallbladder examination of mucosa stained with Geimsa stain and gallbladder rapid urease test ($P < 0.001$), but not correlated with the gastric urease test ($P = 0.210$).

Table 1: General characteristics of studied sample (N=50):

Items	Chronic cellular cholecystitis patients	
Range of age (years) Mean (\pm SD)	18-61 (42.6 \pm 11)	
Female	41	82.0%
Male	9	18.0%
Rural residence	24	48.0%
Urban residence	26	52.0%
BMI mean (\pm SD)	29 \pm 7.2	
BMI class		
-Under weight	3	6.0%
-Normal	13	26.0%
-Overweight	12	24.0%
Obese	22	44.0%
Cholesterol level mean (mg/dl \pm SD)	219 \pm 145	
Triglyceride level mean (mg/dl \pm SD)	121 \pm 52	
H. pylori in stool positive	20	40.0%
H. pylori in stool negative	30	60.0%
H. pylori in tissue positive	19	38.0%
H. pylori in tissue negative	31	62.0%

Table 2: Histopathological findings of patients:

Histopathology	Degree	Number	Percent	Total
Mucosal erosion	Positive	21	42.0	
	Negative	29	58.0	
Mucosal atrophy	Mild	12	24.0	21(42.0%)
	Moderate	9	18.0	
	No	29	58.0	
Mucosal Hyperplasia	Mild	13	26.0	18(36.0%)
	Moderate	5	10.0	
	No	32	64.0	
Metaplasia	Yes	5	10.0	
	No	45	90.0	
Dysplasia	Mild	2	4.0	3(6.0%)
	Moderate	1	2.0	
	No	47	94.0	
**Lymphoid Infiltration	-All through	12	24.0	
	-No	38	76.0	
Musculosa Hypertrophy	Mild	7	14.0	22(44.0%)
	Moderate	10	20.0	
	Severe	5	10.0	
	No	28	56.0	
Fibrosis	Yes	11	22.0	
	No	39	78.0	

**More than one type of lymphoid infiltration in same case: 1/50 cases (2%) with lymphoid aggregates & all through infiltration.

Table 3: Characteristics of *H pylori* +ve and *H pylori* -ve stool patients:

Studied groups	G1(<i>H pylori</i> +ve) No. =20 (100%)	GII (<i>H pylori</i> -ve) No.=30 (100%)	Significance	P.
Age (years) Mean (\pm SD)	44.2 \pm 9.4	41.5 \pm 12	T. =0.8	0.4
Female	16 (80.0%)	25 (83.3%)	X ² =0.09	0.8
Male	4 (20.0%)	5 (16.7%)		
Rural residence	7 (35%)	16 (53.3%)	X ² =0.7	0.4
Urban residence	13 (65%)	14 (46.6%)		
BMI mean (Kg/m ² \pm SD)	31.7 \pm 7.8	27.1 \pm 6.3	T. =2.3	0.02*
Cholesterol level mean (mg/dl \pm SD)	177.8 \pm 44	247 \pm 47	T. =1.2	0.2
Triglyceride level mean (mg/dl \pm SD)	127 \pm 56	116 \pm 49	T. =0.7	0.5
Mucosal erosion +ve	13 (65.0%)	8 (26.7%)	X ² =7	0.007*
Mucosal erosion -ve	7 (35.0%)	22 (73.3%)		
Mucosal atrophy +ve	13 (65.0%)	9 (30.0%)	X ² =6	0.02*
Mucosal atrophy -ve	7 (35.0%)	21 (70.0%)		
Mucosal Hyperplasia +ve	8 (40.0%)	10 (33.3%)	X ² =0.2	0.6
Mucosal Hyperplasia -ve	12 (60.0%)	20 (66.7%)		
Metaplasia +ve	3 (15.0%)	2 (6.7%)	X ² =1	0.3
Metaplasia -ve	17 (85.0%)	28 (93.3%)		
Dysplasia +ve	2 (10.0%)	1 (3.3%)	X ² =0.9	0.3
Dysplasia -ve	18 (90.0%)	29 (94.7%)		
Lymphoid Infiltration +ve	7 (35.0%)	5 (16.7%)	X ² =4	0.2
Lymphoid Infiltration -ve	13 (65.0%)	25 (83.3%)		
Musculosa Hypertrophy +ve	8 (40.0%)	14 (46.7%)	X ² =0.2	0.6
Musculosa Hypertrophy -ve	12 (60.0%)	16 (53.3%)		
Fibrosis +ve	4 (4.0%)	7 (23.3%)	X ² =0.08	0.8
Fibrosis -ve	16 (20.0%)	23 (76.7%)		

Table 4: Comparison between patients with *H pylori* +ve and *H pylori* -ve in tissue:

Studied groups	<i>H pylori</i> +ve No.=19 (100%)	<i>H pylori</i> -ve No.=31 (100%)	Significance	P.
Age (years) Mean (\pm SD)	46.2 \pm 9	40.4 \pm 11	T. =1.9	0.07
Female	15 (78.9%)	26 (83.9%)	X ² =0.2	0.6
Male	4 (21.1%)	5 (16.1%)		
Rural residence	6 (31.5%)	16 (51.6%)	X ² =0.7	0.4
Urban residence	13 (68.4%)	15 (48.4%)		
BMI mean (Kg/m ² \pm SD)	30.6 \pm 8.6	28 \pm 6	T. =1.3	0.2
Cholesterol level mean (mg/dl \pm SD)	179 \pm 57	244 \pm 74	T. =1	0.3
Triglyceride level mean (mg/dl \pm SD)	125 \pm 55	118 \pm 50	T. =0.4	0.7
Mucosal erosion +ve	13 (68.4%)	8 (25.8%)	X ² =9	0.003*
Mucosal erosion -ve	6 (31.6%)	23 (74.2%)		
Mucosal atrophy +ve	12 (63.2%)	10 (32.3%)	X ² =4.5	0.03*
Mucosal atrophy -ve	7 (36.8%)	21 (67.7%)		
Mucosal Hyperplasia +ve	11 (57.9%)	7 (22.6%)	X ² =6	0.012*
Mucosal Hyperplasia -ve	8 (42.1%)	24 (77.4%)		
Metaplasia +ve	5 (26.3%)	0 (0.0%)	X ² =9	0.003*
Metaplasia -ve	14 (73.7%)	31 (100%)		
Dysplasia +ve	2 (10.5%)	1 (3.2%)	X ² =1.1	0.3
Dysplasia -ve	17 (89.5%)	30 (96.8%)		
Lymphoid Infiltration +ve	8 (42.1%)	4 (12.9%)	X ² =7	0.02*
Lymphoid Infiltration -ve	11 (57.9%)	27 (87.1%)		
Musculosa Hypertrophy +ve	8 (42.1%)	14 (45.2%)	X ² =0.05	0.8
Musculosa Hypertrophy -ve	11 (57.9%)	17 (54.8%)		
Fibrosis +ve	5 (26.3%)	6 (19.4%)	X ² =0.3	0.6
Fibrosis -ve	14 (73.7%)	25 (80.6%)		

Table 5: Correlation between *H. pylori*-specific antigens in stool and in tissue:

<i>H. pylori</i> - in tissue	<i>H. pylori</i> -specific antigens in stool
<i>r.</i>	0.5
<i>p.</i>	0.000*

In 140 patients with chronic calculous cholecystitis, the rapid urease test was positive in gallbladder mucosa of 35 patients (25%), and negative in 105 patients (75%) while on histological examination after modified Geimsa staining, *H. pylori*-like bacteria were in 89 patients (63.6%). They concluded that *H. pylori* was present in the gallbladder mucosa in patients with chronic calculous cholecystitis as an etiological cause of chronic inflammation.

In the present study, histopathologically, the most predominant finding was muscular hypertrophy (44%), mucosal atrophy (42%), mucosal erosion (42%), lymphoid aggregates all over mucosa (24%), while gallbladder wall fibrosis (22%). Mucosal hyperplasia was in 36%, metaplasia was in 10% and dysplasia was in 6%.

Misran *et al.* (2007) assessed the prevalence of *H. pylori* in patients with gastric carcinoma and correlate it with gross appearance and histological type. They found a significant association between *H. pylori* and grades of gastritis ($P < 0.01$) in controls as well as in patients but it failed to show a significant association with tumor grades, intestinal metaplasia, tumor site and patients' ages. So, prevalence of *H. pylori* infection was not directly associated with pathogenesis of gastric cancer but it may act as a co-carcinogen by damaging the mucosa and thereby making it more susceptible to effects of carcinogen.

In the present study, there was no significant difference between *H. pylori* Ag +ve and -ve in stool as regard histopathological changes except for mucosal erosion and mucosal atrophy that showed significant difference between the two groups ($p=0.007$ & 0.02 respectively). Jeongmin *et al.* (2011) evaluated stool antigen test for the detection of *H. pylori* in comparison with histology,

rapid urease test, ¹³C-urea breath test, and serology found that sensitivity, specificity, positive and negative predictive values, and accuracy of stool antigen test were 93.1%, 94.6%, 95.1%, 92.3%, & 93.8%, respectively. The sensitivity of histology, rapid urease test, and ¹³C-urea breath test ranged from 89.1% to 97.6%, specificity was > 98%, and serology had high sensitivity, but low specificity. The accuracy of the stool antigen test was comparable to that of other methods (93.6–95.9%), whereas it was higher than that of serology.

In the present study, comparison between patients with *H. pylori* +ve in tissue and -ve in tissue, showed statistically significant differences as regard histopathological changes in mucosal erosions ($p=0.003$), mucosal atrophy ($p=0.03$), mucosal hyperplasia ($p=0.012$), metaplasia ($p=0.003$) and lymphoid infiltration ($p=0.02$). De Moricz *et al.* (2010) reported that gallbladders with metaplasia and follicles displayed statistically significant contrasts when associated with lymphoid follicles in the mucosa of gallbladder (follicular cholecystitis) and the existence of bacilli.

Misra *et al.* (2007) emphasized that preneoplastic histological changes were in the gallbladder mucosa, restricted to infection with *Helicobacter* spp., for instance, intestinal metaplasia, hyperplasia, dysplasia, eosinophilic inflammation, and hyalinosis. Also, Dong-Feng *et al.* (2007) reported that metaplasia provided suitable conditions for *H. pylori* colonization in gallbladder. By EM revealed at sites infected with *H. pylori*, the integrity of the cell-to-cell membrane of gallbladder epithelium was destructed, with swelling of mitochondria and dilatation of endoplasmic reticulum. In *H. pylori*-infected gallbladder mucosa, metaplasia lesions area accompanying with *H. pylori* colonization

could be detected in 91.5% of the specimens. The morphological data may indicate a potential direction for determining the role of *H. pylori* in the formation of metaplasia.

Generally speaking, in Egypt Aziz *et al.* (2015) stated that on dealing with waterborne infections, one might give priority to infectious diseases with high mortality such as cholera and other diarrheal diseases. However, *H. pylori* might cause cancer especially in elderly patients and given that life expectancy has increased, and so poverty, preventing infection-associated cancers (e.g., *H. pylori* and hepatitis C) should be a priority of health organizations in the decades to come.

Conclusion

Helicobacter pylori Ag in stool is a simple, reliable non-invasive technique should be applied for detection of *H. pylori* infection in chronic calcular cholecystitis and to monitor the success of eradication treatment.

The data proved that *H. pylori* infection could be one of the etiological factors of cholecystolithiasis. *Helicobacter pylori* correlated with gallbladder premalignant lesions including atrophy, hyperplasia, metaplasia and lymphoid infiltration. The precise mechanism requires further research.

Recommendations

1- Epidemiological studies are indicated to cover Egyptian districts with special attention to socioeconomic status, other associated organisms, other associated diseases, environmental factors exploration and genetic factors.

2-*H. pylori* eradication is a must especially in childhood. Also, other co-parasites and/or micro-organisms, if present must be diagnosed and treated as well.

3- Experimental studies are needed to explore behavior, etiology and host-parasite relationship of *H. pylori*.

References

Apostolov, E, Al-Soud, WA, Nisson, I, Kornilovska, I, Usenko, V, *et al*, 2005:*Helicobacter pylori* and other *Helicobacter* species in gallbladder and liver of patients with chronic chole-

cystitis by immunological and molecular methods. Scand. J. Gastroenterol. 40, 1:96-102.

Aziz RK, Khalifa M, Sharaf R, 2015: Contaminated water as a source of *Helicobacter pylori* infection: a review. J. Adv. Res. 6, 4:539-47.

Cintia, PS, Carlos JP, Oliviera AG, Guerra, JB, Marques DL, *et al*, 2003: Association of the presence of *Helicobacter* in gallbladder tissue with cholelithiasis and cholecystitis. J. Clin. Microbiol. 41, 12:5615-8.

De Moricz, A, Melo, M, Castro, AM, de Campos, T, Silva, RA, *et al*, 2010: Prevalence of *Helicobacter*sp in chronic cholecystitis and correlation with changes on the histological pattern of the gallbladder. Acta Cir. Bras. 25, 3:218-24.

Dong-Feng, C, Hu, L, Yi, P, *et al*, 2007:*H. pylori* are associated with chronic cholecystitis. World J. Gastroenterol. 13, 7:1119-22.

El-Fakhfakh, EA, Montasser, IF, Khalifa, RA, 2014: Evaluation of salivary and serum anti-*Helicobacter pylori* in Egyptian patients with *H. pylori* related gastric disorders. J. Egypt. Soc. Parasitol. 44, 1:275-83.

El-Omar, EM, Penman, ID, Ardill, JES, Chittajallu, RS, Howie, C, *et al*, 1995:*Helicobacter pylori* infection and abnormalities of acid secretion in patients with duodenal ulcer disease. Gastroenterol.109:681-91

Fekry, AA, Kasseem, AA, Shahin, D, Shabana, Hosam, AS, Mostafa, S, 2014:*Helicobacter pylori* infection in patients with chronic calcularcholecystitis a cross- sectional study. J. Surg, 2, 4:58-62.

Ghzal, A, Elsabbagh, N, El-Riwini, M, 2001: Presence of *Helicobacter* sp.DNA in the gallbladder of Egyptian patients with gallstone diseases. EMHJ. 17, 12:925-9.

Gisbert, JP, de la Morena, F, Abaira, V, 2006: Accuracy of monoclonal stool antigen test for the diagnosis of *H. pylori* infection: A systematic review and meta-analysis. Am. J. Gastroenterol. 101:1921-30.

Gisbert, JP, Pajares, JM, 2004: Stool antigen test for diagnosis of *Helicobacter pylori* infection: a systematic review. *Helicobacter* 9:347-68

Hansen, S, Melby, KK, Aase, S, Jellum, E, Vollset, SE, 1999: *Helicobacter pylori* infection and risk of cardia cancer and non-cardia gastric cancer: a nested case-control study. Scand. J. Gastroenterol. 34:353-60

Jeongmin, C, Kim, C.H, Kim, D, Chung, SJ, Song, JH, *et al*, 2011: Prospective evaluation of

a new stool antigen test for the detection of *Helicobacter pylori*, in comparison with histology, rapid urease test, 13C-urea Breath Test, and Serology. J. Gastroenterol. Hepatol. 26, 6:1053-9.

Kawaguchi, M, Saito, T, Ohno, H, et al, 1996: Bacteria closely resembling *Helicobacter pylori* detected immunohistochemically and genetically in resected gallbladder mucosa. J. Gastroenterol 31, 2:294-8.

Lee, JW, Lee, DH, Lee, JI, Jeong, S, Kwon, K S, et al, 2010: Identification of *Helicobacter pylori* in gallstone, bile, and other hepatobiliary tissues of patients with cholecystitis. Gut Liver 4: 60-7.

Misra, V, Misra, SP, Dwivedi, M, Shouche, Y, Dharne, M, et al, 2007: *Helicobacter pylori* in areas of gastric metaplasia in the gallbladder and

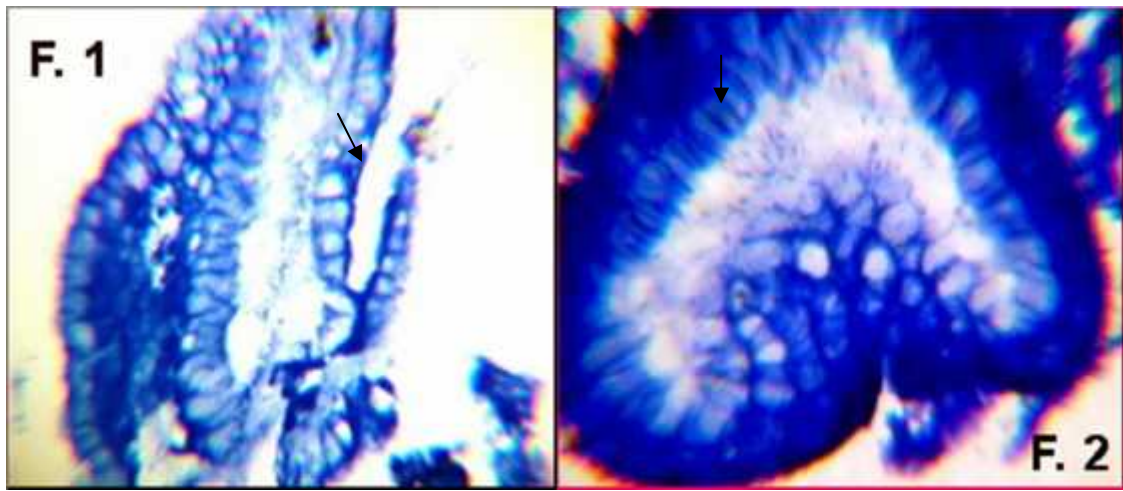
isolation of *H. pylori* DNA from gall-stones. Pathol. 39, 4:419-24.

Murphy, G, Michel, A, Taylor, PR, Albanes, D, Weinstein, SJ, et al, 2014: Association of seropositivity to Helicobacter species and biliary tract cancer in the ATBC study. Hepatology 60, 6:1963-71.

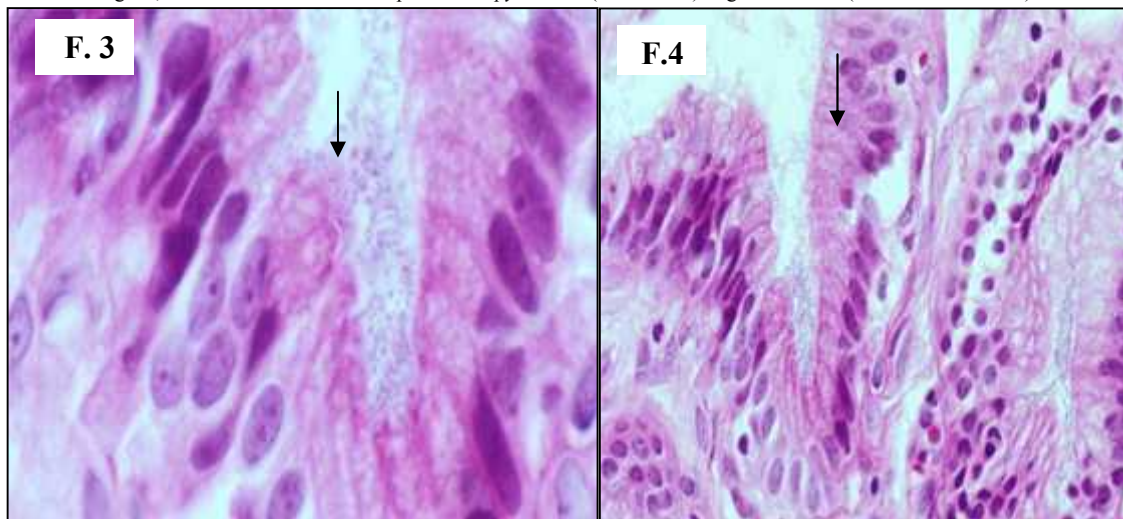
Parsonnet, J, Hansen, S, Rodriguez, L, et al, 1994: *Helicobacter pylori* and gastric lymphoma. N. Engl. J. Med. 330:1267-71

Warren, JR, Marshall, BJ, 1983: Unidentified curved bacilli on gastric epithelium in active chronic gastritis. Lancet 1:1273-5.

WGO, 2011: World Gastroenterology Organization; world gastroenterology organization global guidelines: helicobacter pylori in developing countries. J. Digest. Dis. 12:319-26



Figs: 1,2 Gallbladder mucosa with positive *H. pylori* like (arrow head) in glands lumen (Giemsa stain X-400).



Figs. 3, 4: Mildly inflamed gallbladder mucosa with *H. pylori* (arrow head) at surface (H&E stain X-400)